

## HOSPICE & PALLIATIVE WOUND CARE

Patients with life-limiting illnesses experience the failure of one or more major organ systems. The skin is the largest organ in the body and can also fail. As a result, wounds may not follow the usual trajectory of healing. Caring for an open wound presents unique challenges in hospice and palliative care. Inadequate tissue perfusion and oxygenation, excessive skin moisture, immobility due to pain, a compromised immune system, and poor nutrition are factors that can impact wound healing, contribute to the loss of skin integrity, and cause progressive wound deterioration.

Common types of wounds encountered in hospice and palliative care include pressure ulcers, fungating tumors, lower-extremity ulcers, moisture-associated skin damage, and skin tears. Wound closure may be achieved if the underlying etiology and barriers to healing can be corrected. Comfort, self-esteem, patient preference, and overall quality of life remain the primary foci.<sup>1</sup>

### Wound Assessment

For patients with existing wounds, perform a wound assessment on admission, weekly, and if the patient's condition deteriorates. Key clinical observations include:

- Etiology
- Anatomical location
- Size (length, width, and depth)
- Type and amount of exudate
- Type and amount of necrotic tissue
- Extent of undermining and tunneling
- Quantity and quality of granulation and epithelial tissue
- Condition of peri-wound skin
- Wound odor
- Wound-related pain

Wound imaging can supplement your documentation of wound status. Wound photographs help document progress or lack of progress toward the desired outcome. Wound photos should not be taken if your organization does not have HIPAA-governed policies and protocols in place to support them.

If a patient presents with a pressure ulcer (pressure ulcers constitute more than 50% of wounds encountered at the end of life), it is recommended to use the National Pressure Injury Advisory Panel guidelines to assess ulcer stage.<sup>2</sup> Note that although the panel has changed its terminology to “pressure injury,” the International Statistical Classification of Diseases and Related Health Problems, 10<sup>th</sup> revision, and other mandated documentation (e.g., Minimum Data Set) still use “pressure ulcer.”

Pressure-related pain can range from mild to severe and can be cyclic or constant. Patients typically describe early ischemia over a bony prominence as “a sensitive, burning sensation.” The number of descriptors used to communicate pressure-related pain tends to increase with the severity of injury.<sup>3,4</sup> Additionally, be mindful that stage I pressure ulcers and deep-tissue injuries present differently and are harder to differentiate in darkly pigmented skin.

The location, shape, and moisture content of lower-extremity wounds help determine the underlying etiology. Generally, ulcers associated with peripheral arterial disease or diabetes have minimal drainage, have well-defined margins, and involve sites of trauma on the feet or ankles. On the other hand, venous ulcers tend to have moderate to heavy drainage, have diffuse or irregular margins, and occur on the gaiter (sock) area of the leg.<sup>5</sup>

Rapid wound deterioration or the sudden appearance of new wounds may occur as a result of “skin changes at life’s end” (SCALE). SCALE is caused by blood being shunted away from the skin to perfuse vital organs. Dusky erythema, mottled discoloration, and coolness of the skin on palpation are signs that skin is failing. Infarcts and gangrene eventually occur, resulting in unavoidable wounds caused by progressive ischemia. The Kennedy terminal ulcer is one example of an unavoidable SCALE pressure ulcer.<sup>6,7</sup>

## INTERVENTIONS

In general, wounds can be divided into three categories to help determine a patient's healing potential:<sup>8</sup>

- **Healable:** The wound has a good blood supply, and the underlying etiology can be addressed.
- **Maintenance:** The wound has healing potential, but barriers exist that compromise healing.
- **Non-healable:** The wound cannot heal because of the etiology, factors that delay healing, or comorbidities that cannot be treated.

Approach every wound in palliative care with the possibility of healing in mind. If healing potential is questionable, consider a two- to four-week “intent to treat” trial and monitor wound progress. If the wound is non-healable or fails to respond to treatment, symptom management should always take priority over painful procedures such as aggressive debridement and cleansing. Documentation about healing potential or reasons a wound is not healing is critical, especially when wound deterioration is unavoidable due to the patient's overall condition. Another important intervention is to consider appropriate support surfaces for offloading and positioning to reduce frictional forces and for pressure injury prevention and treatment. The Wound, Ostomy, and Continence Nurses Society's support surface algorithm (<http://algorithm.wocn.org/#home>) can be downloaded to a mobile device.<sup>8</sup> Educate patients and families about why a wound may or may not heal, align therapy to goals, and document education and goals of care.

Symptom	Goal(s)	Interventional Options
Dry, adherent eschar <sup>9</sup>	<ul style="list-style-type: none"> <li>• Maintain a closed, stable eschar</li> <li>• Avoid discomfort and complications of an open wound</li> </ul>	<ul style="list-style-type: none"> <li>• Topical 10% povidone iodine</li> <li>• Leave open to air</li> <li>• Dry gauze dressing</li> <li>• Avoid contact with moisture</li> </ul>

Symptom	Goal(s)	Interventional Options
Wet, separating eschar and soft slough <sup>4</sup>	<ul style="list-style-type: none"> <li>• Non-aggressive debridement</li> <li>• Manage local symptoms of infection</li> </ul>	<ul style="list-style-type: none"> <li>• Dressing to promote autolytic debridement (hydrogel, alginate, hydrofiber, foam, or hydrocolloid)</li> <li>• Enzymatic or maggot debridement if feasible</li> <li>• Topical antimicrobial or bacteriostatic dressing to manage infection*</li> </ul>
Dry, fibrotic granulation tissue	<ul style="list-style-type: none"> <li>• Add moisture</li> </ul>	<ul style="list-style-type: none"> <li>• Hydrogel dressing</li> <li>• Ointment-impregnated gauze</li> </ul>
Pain <sup>1,3,4,10,11</sup>	<ul style="list-style-type: none"> <li>• Promote comfort</li> <li>• Improve quality of life</li> </ul>	<ul style="list-style-type: none"> <li>• Nonadherent dressing</li> <li>• RGN107 topical powder</li> <li>• Ibuprofen foam dressing</li> <li>• Topical opiate or anesthetic</li> <li>• Hydrogel sheets in fridge</li> </ul>
Excessive bleeding <sup>1,4,11</sup>	<ul style="list-style-type: none"> <li>• Control bleeding during dressing changes</li> </ul>	<ul style="list-style-type: none"> <li>• Moisten dressing prior to removal</li> <li>• Gentle cleansing or irrigation</li> <li>• Pressure (10-15 minutes)</li> <li>• Alginate dressing</li> <li>• Non-adherent contact layer</li> <li>• RGN107 topical powder</li> </ul>

Symptom	Goal(s)	Interventional Options
Excessive bleeding <sup>1,4,11</sup> (cont.)		<ul style="list-style-type: none"> <li>• Topical hemostatic agent               <ul style="list-style-type: none"> <li>◦ Silver nitrate sticks or 10% solution</li> <li>◦ Epinephrine (1:1,000 solution)</li> <li>◦ Clotting agent</li> <li>◦ Afrin (off label)</li> </ul> </li> <li>• Dark towels to allay anxiety</li> </ul>
Foul odor <sup>1,4,10,11</sup>	<ul style="list-style-type: none"> <li>• Reduce anaerobic and gram-negative bacterial load</li> </ul>	<ul style="list-style-type: none"> <li>• Topical metronidazole (can crush tablet)</li> <li>• Activated charcoal, carbon, silver foam, or honey dressing</li> <li>• 0.25% Dakin solution</li> <li>• Control environmental odor (activated charcoal, kitty litter, vinegar, vanilla, coffee beans, burning candle, etc.)</li> </ul>
Excessive exudate <sup>1,4,10</sup>	<ul style="list-style-type: none"> <li>• Decrease frequency of dressing changes</li> </ul>	<ul style="list-style-type: none"> <li>• Alginate, hydrofiber, foam, or superabsorbent polymer dressing</li> <li>• Protect peri-wound skin from maceration</li> <li>• Consider use of baby diapers or adult briefs if would have large surface area</li> <li>• Topical antimicrobial or bacteriostatic dressing to manage infection*</li> </ul>

\* Advanced dressings typically provide a bacteriostatic product category option.

**PATIENT & FAMILY SUPPORT**

- Collaborate with the patient and family to establish realistic wound care goals.
- Educate the patient and family about:
  - ▶ The importance of offloading pressure and minimizing friction/shear.
  - ▶ How and when to perform a dressing change.
  - ▶ Notification criteria for clinical support.
- Prepare the patient and family in advance if excessive bleeding is expected during dressing changes.
- Ensure that oral pain medications have time to reach a therapeutic level prior to dressing change.
- Consider the need for interprofessional referrals for nutritional support, mobilization, and assistance with activities of daily living to optimize healing potential.

**SYMPTOM DOCUMENTATION EXAMPLE****79 yr old patient with a history of chronic obstructive pulmonary disease (COPD)**

is receiving palliative care for severe fatigue after treatment for an upper respiratory infection. Patient's condition has progressively declined over the past several weeks due to COPD end-stage disease progression. Nutritional intake is inadequate despite spouse's attempts to offer small meals and oral supplements. Patient presents at visit with an unstageable sacral pressure ulcer. There is a moderate amount of purulent drainage with a foul odor. The wound was irrigated with saline and an activated charcoal alginate dressing applied. Spouse was able to provide a return demonstration of the dressing procedure and recall in-home wound-management plan. Reviewed appropriate positioning to offload sacrum as much as possible while also maintaining patient's comfort. Expectation of continued decline with unavoidable wound deterioration was discussed with the family and prescriber, who agreed to conservative symptom-management approach.

**DESIRED NURSING OUTCOMES**







- Improve quality of life for the patient and family by adopting a holistic approach to wound care based on healing potential.

- Relieve pain and suffering and improve quality of life when a wound no longer responds to curative treatment.
- The family verbalizes that the wound odor is less noticeable, and they are able to perform wound dressing at bedside by next nursing visit.

## REFERENCES

1. Woo KY, Krasner DL, Kennedy B, Wardle D, Moir O. Palliative wound care management strategies for palliative patients and their circles of care. *Advances in Skin & Wound Care*. 2015;28(11):130-140.
2. Edsberg LE, Black JM, Goldberg M, McNichol L, Moore L, Sieggreen M. Revised NPUAP Pressure Injury Staging System. *Journal of Wound, Ostomy, and Continence Nursing*. 2016;43(6):585-597.
3. Girouard K, Harrison MB, VanDenKerkof E. The symptom of pain with pressure ulcers: a review of the literature. *Ostomy-Wound Management*. 2008;54(5):30-42.
4. Langemo DK, Black J, National Pressure Ulcer Advisory Panel. Pressure ulcers in individuals receiving palliative care: a National Pressure Ulcer Advisory Panel white paper. *Advances in Skin and Wound Care*. 2010;23(2):59-72.
5. Hess CT. Lower-extremity wound checklist. *Advances in Skin & Wound Care*. 2011;24(3):144.
6. Sibbald RG, Krasner DL, Lutz J. SCALE: final consensus statement. *Advances in Skin & Wound Care*. 2010;23(5):225-236.
7. Ayello EA, Jeffrey L, Langemo D, et al. Reexamining the literature on terminal ulcers, SCALE, skin failure, and unavoidable pressure injuries. *Advances in Skin and Wound Care*. 2019;32(3):109-121. doi: 10.1097/01.ASW.0000553112.55505.5f.
8. McNichol L, Mackey D, Watts C, et al. Choosing a support surface for pressure injury prevention and treatment. *Nursing*. 2020;50(2):41-44. doi: 10.1097/01.NURSE.0000651620.87023.d5.
9. Kelechi TJ, Prentice M, Madisetti M, Brunette G, Mueller M. Palliative care in the management of pain, odor, and exudate at the end of life. *Journal of Hospice & Palliative Nursing*. 2017;19(1):17-25.
10. Sibbald RG, Elliot JA, Ayello EA, Somayaji R. Optimizing the moisture management tightrope with wound bed preparation 2015. *Advances in Skin and Wound Care*. 2015;28(10):466-476.
11. Graves ML, Sun V. Providing quality wound care at the end of life. *Journal of Hospice & Palliative Nursing*. 2013;15(2):66-74.

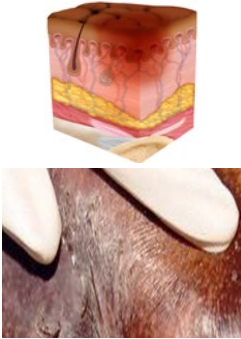





# NPIAP STAGING FOR LIGHTLY PIGMENTED SKIN

					
<p><b>STAGE 1 PRESSURE INJURY: NON-BLANCHABLE ERYTHEMA OF INTACT SKIN</b></p> <p>Intact skin with a localized area of non-blanchable erythema, which may appear differently in darkly pigmented skin. Presence of blanchable erythema or changes in sensation, temperature, or firmness may precede visual changes. Color changes do not include purple or maroon discoloration; these may indicate deep tissue pressure injury.</p>	<p><b>STAGE 2 PRESSURE INJURY: PARTIAL-THICKNESS SKIN LOSS WITH EXPOSED DERMIS</b></p> <p>Partial-thickness skin loss with exposed dermis. The wound bed is viable, pink or red, moist, and may also present as an intact or ruptured serum-filled blister. Adipose (fat) is not visible and deeper tissues are not visible. Granulation tissue, slough and eschar are not present. These injuries commonly result from adverse microclimate and shear in the skin over the pelvis and shear in the heel.</p>	<p><b>STAGE 3 PRESSURE INJURY: FULL-THICKNESS SKIN LOSS</b></p> <p>Full-thickness loss of skin, in which adipose (fat) is visible in the ulcer and granulation tissue and epibole (rolled wound edges) are often present. Slough and/or eschar may be visible. The depth of tissue damage varies by anatomical location; areas of significant adiposity can develop deep wounds. Undermining and tunneling may occur. Fascia, muscle, tendon, ligament, cartilage or bone is not exposed. If slough or eschar obscures the extent of tissue loss this is an Unstageable Pressure Injury.</p>	<p><b>STAGE 4 PRESSURE INJURY: FULL-THICKNESS LOSS OF SKIN AND TISSUE</b></p> <p>Full-thickness skin and tissue loss with exposed or directly palpable fascia, muscle, tendon, ligament, cartilage or bone in the ulcer. Slough and/or eschar may be visible. Epibole (rolled edges), undermining and/or tunneling often occur. Depth varies by anatomical location. If slough or eschar obscures the extent of tissue loss this is an Unstageable Pressure Injury.</p>	<p><b>UNSTAGEABLE PRESSURE INJURY: OBSCURED FULL-THICKNESS SKIN AND TISSUE LOSS</b></p> <p>Full-thickness skin and tissue loss in which the extent of tissue damage within the ulcer cannot be confirmed because it is obscured by slough or eschar. If slough or eschar is removed, a Stage 3 or Stage 4 pressure injury will be revealed. Stable eschar (i.e. dry, adherent, intact without erythema or fluctuance) on an ischemic limb or the heel(s) should not be softened or removed.</p>	<p><b>DEEP TISSUE PRESSURE INJURY: PERSISTENT NON-BLANCHABLE DEEP RED, MAROON OR PURPLE DISCOLORATION</b></p> <p>Intact or non-intact skin with localized area of persistent non-blanchable deep red, maroon, purple discoloration or epidermal separation revealing a dark wound bed or blood-filled blister. Pain and temperature change often precede skin color changes. Discoloration may appear differently in darkly pigmented skin. This injury results from intense and/or prolonged pressure and shear forces at the bone-muscle interface.</p>

A pressure injury is localized damage to the skin and underlying soft tissue usually over a bony prominence or related to a medical or other device. The injury can present as intact skin or an open ulcer and may be painful. The injury occurs as a result of intense and/or prolonged pressure or pressure in combination with shear. The tolerance of soft tissue for pressure and shear may also be affected by microclimate, nutrition, perfusion, co-morbidities and condition of the soft tissue.



# NPIAP STAGING FOR DARKLY PIGMENTED SKIN

 <p><b>STAGE 1 PRESSURE INJURY: NON-BLANCHABLE ERYTHEMA OF INTACT SKIN</b></p> <p>Intact skin with a localized area of non-blanchable erythema, which may appear differently in darkly pigmented skin. Presence of blanchable erythema or changes in sensation, temperature, or firmness may precede visual changes. Color changes do not include purple or maroon discoloration; these may indicate deep tissue pressure injury.</p>	 <p><b>STAGE 2 PRESSURE INJURY: PARTIAL-THICKNESS SKIN LOSS WITH EXPOSED DERMIS</b></p> <p>Partial-thickness skin loss with exposed dermis. The wound bed is viable, pink or red, moist, and may also present as an intact or ruptured serum-filled blister. Adipose (fat) is not visible and deeper tissues are not visible. Granulation tissue, slough and eschar are not present. These injuries commonly result from adverse microclimate and shear in the skin over the pelvis and shear in the heel.</p>	 <p><b>STAGE 3 PRESSURE INJURY: FULL-THICKNESS SKIN LOSS</b></p> <p>Full-thickness loss of skin, in which adipose (fat) is visible in the ulcer and granulation tissue and epibole (rolled wound edges) are often present. Slough and/or eschar may be visible. The depth of tissue damage varies by anatomical location; areas of significant adiposity can develop deep wounds. Undermining and tunneling may occur. Fascia, muscle, tendon, ligament, cartilage or bone is not exposed. If slough or eschar obscures the extent of tissue loss this is an Unstageable Pressure Injury.</p>	 <p><b>STAGE 4 PRESSURE INJURY: FULL-THICKNESS LOSS OF SKIN AND TISSUE</b></p> <p>Full-thickness skin and tissue loss with exposed or directly palpable fascia, muscle, tendon, ligament, cartilage or bone in the ulcer. Slough and/or eschar may be visible. Epibole (rolled edges), undermining and/or tunneling often occur. Depth varies by anatomical location. If slough or eschar obscures the extent of tissue loss this is an Unstageable Pressure Injury.</p>	 <p><b>UNSTAGEABLE PRESSURE INJURY: OBSCURED FULL-THICKNESS SKIN AND TISSUE LOSS</b></p> <p>Full-thickness skin and tissue loss in which the extent of tissue damage within the ulcer cannot be confirmed because it is obscured by slough or eschar. If slough or eschar is removed, a Stage 3 or Stage 4 pressure injury will be revealed. Stable eschar (i.e. dry, adherent, intact without erythema or fluctuance) on an ischemic limb or the heel(s) should not be softened or removed.</p>	 <p><b>DEEP TISSUE PRESSURE INJURY: PERSISTENT NON-BLANCHABLE DEEP RED, MAROON OR PURPLE DISCOLORATION</b></p> <p>Intact or non-intact skin with localized area of persistent non-blanchable deep red, maroon, purple discoloration or epidermal separation revealing a dark wound bed or blood-filled blister. Pain and temperature change often precede skin color changes. Discoloration may appear differently in darkly pigmented skin. This injury results from intense and/or prolonged pressure and shear forces at the bone-muscle interface.</p>
--	---	--	--	---	---

## TIPS FOR STAGING DARKLY PIGMENTED SKIN:

- Moisten the skin
- Inspect for changes in pigmentation
- Palpate for edema
- Ask about pain in the area
- Avoid direct light